

# An aesthetic and biomimetic approach with a glass hybrid for direct restorations

by Ass. Prof. **Zeynep Bilge Kütük**, Turkey



**Assistant Prof. Zeynep Bilge Kütük** graduated from Hacettepe University School of Dentistry in 2007 and started her doctoral studies at the Department of Restorative Dentistry from the same university in 2009. She went to the research laboratories of the Restorative Dentistry Department of Ludwig Maximilians University in Munich, Germany, with a scholarship of the Continental European Division (CED/IADR) of the International Association for Dental Research (IADR). She obtained her PhD in 2015. She received the title of Assistant Professor in 2017. She has been a member of the IADR since 2009. She has published several articles in international and national journals. She participated in several international trainings on minimally invasive aesthetic applications and is a trainer in hands-on courses on aesthetic restorations with current approaches.

Glass ionomer (GI) was first introduced in the 1970s<sup>1</sup>.

Currently, it is extensively being used for cores, bases/liners, and the cementation of posts, crowns, and fixed bridges.

Although, they have numerous advantages, the first GIs were thought to be too rough or unaesthetic due to their opacity for anterior restorations and not durable enough for posterior restorations. However, GIs have been greatly improved since they were first introduced. Many of those earlier concerns have now been fully addressed by manufacturers.

In 2007, EQUIA was launched, a restorative system comprising a GI and a synergistic light-cured nano-filled coating agent. It became the first GI-based system that was indicated for permanent Class II restorations, albeit with cavity size restrictions. Eight years later, the first glass hybrid system, EQUIA Forte, was launched, based on the success of EQUIA.

Owing to the new glass hybrid filler technology, the indications for EQUIA Forte could be extended to load-bearing Class II restorations (without cusp involvement). While composite resins are often the first choice for direct aesthetic restorations, specific features of GIs may make them a better choice in certain indications.

## An aesthetic and biomimetic approach with a glass hybrid for direct restorations

The overall goal of this article is to provide the clinician with an overview of the information on a newly developed glass hybrid system (EQUIA Forte HT) and as well as to give useful application tips based on results from clinical cases.

### Bulk-fill properties

EQUIA and EQUIA Forte restorative systems are both placed easily in 'bulk' directly in a cavity, very similar to amalgam, without limitations in depth of cure. Moreover, they can be placed in a short time (around 3 min) and without any adhesive procedure. For this reason, they are truly one of the best choices for bulk fill application method. They do not generate the shrinkage stresses that occur in composite restorations and their elastic modulus is very closed to dentine, which makes them a unique biomimetic dentine replacement material.

GIs and glass hybrids form an ionic chemical bond to the calcium found in the hydroxyapatite of both enamel and dentine. Though cleaning the cavity with a mild cavity conditioner (10 or 20% polyacrylic acid) is beneficial, no surface pretreatment is required. The adhesion of GI to tooth structure is less technique sensitive than composite resins and its quality increases with time<sup>2</sup>. In 2005, Peumans *et al.*<sup>3</sup> reported that GI restoratives exhibited superior retention and clinical performance than adhesive resin systems.

On the other hand, composite resins always require a clean field and should

ideally be placed under a rubber dam to prevent contamination during placement.

### Favourable physical and biological properties

Reconstructions of posterior teeth with deep caries lesions are still a challenge for restorative dentistry because of the absence of sufficiently resistant restorative materials with favourable biological properties. Previously, GIs had their limitations in load-bearing areas due to their lower physical properties, and necessitated regular monitoring if placed as a permanent restoration<sup>4</sup>.

The light-cure resin coating application (EQUIA Coat and EQUIA Forte Coat) of the EQUIA and EQUIA Forte restorative systems makes them more aesthetic and gives a shiny appearance to the restorations, seals the margins, provides wear resistance and protects from early moisture sensitivity until maturation is completed, resulting in a high compressive strength.

Based on my clinical experiences I could express that the use of encapsulated forms GI and glass hybrid restorative systems minimises variations in handling and give satisfying outcomes in teeth with deep carious lesions, especially in young patients.

The best-known property of GIs is constant release of fluoride. Immediately after the contact of the acids to the surface of GI restoration, fluoride ions are release from the surface and neutralise them. The

fluoride ions can be resorbed by the GI restoration and recharge it for the next acid challenge when teeth are brushed with a fluoride toothpaste, or a fluoride oral rinse is used. The polymer matrix of composite resins, on the contrary, does not allow ion exchange with the oral environment. When some soft infected dentine was left over the pulp wall by sealing the cavity with a bioactive material like GI, the caries progression arrested and sometimes even regressed. Besides their role in remineralisation, fluorides, calcium, phosphate and strontium ions transfer from GI into the deep demineralised dentine. So, the pulp can remain vital without any pulp capping agents and postoperative sensitivity<sup>5</sup>.

### The benefits of glass hybrid technology

What differentiates glass hybrid from other conventional GI restoratives is its chemistry. The highly reactive fluoro-alumino-silicate (FAS) micron-sized fillers (<4 µm) were added to the standard FAS glass filler particles of EQUIA Fil. The micron-sized filler particles release more metal ions, which improve the cross-linking of the polyacrylic acid matrix and the overall physical properties. Additionally, EQUIA Forte Fil liquid comprises a high-molecular-weight polyacrylic acid, which helps to improve the chemical stability, acid resistance, and physical properties of the set cement. The light-cured, nano-filled resin coating (EQUIA Forte Coat) was improved by incorporating a reactive multifunctional monomer that increases resistance to wear, has a higher

polymerisation conversion and thinner film layer, and also provides a smoother surface to the final restoration.

### Long-term clinical trials

Long-term clinical studies of the EQUIA restorative system were reported, exhibiting clinically successful outcomes in Class I and Class II lesions<sup>6-10</sup>. Under the guidance of Professor Gurgan, we evaluated the clinical performance of EQUIA restorative system in conservative Class I and II cavities and

compared it with a micro-hybrid composite (Gradia Direct Posterior/GC). Nowadays, this 8-year evaluation of this clinical trial has been completed. According to results of this trial, both tested restorative materials showed an acceptable success rate after 8 years. EQUIA restorative system has been used as a routine restorative in the treatment of permanent teeth in Hacettepe University School of Dentistry Restorative Dentistry Clinics, where I performed my clinical studies since 2009<sup>11</sup>.

In 2015, we started another clinical trial again under the guidance of Professor Gurgan and evaluated the clinical performance of EQUIA Forte restorative system in large Class-II cavities and compared with a micro-hybrid composite (G-aenial Posterior, GC). According to results of our clinical trial, EQUIA Forte restorations showed negligible retention failure and mismatch in colour, both restorative materials exhibited successful performances for the restoration of large Class II cavities after 24 months<sup>12</sup>.

### To improve the clinical success of these restorations, following elements are important:

1. To respect the cavity size indications
2. The use of preformed metal sectional matrix systems to restore multi-surface cavity preparations
3. To keep prepared surfaces moist (glistening). Do not desiccate!
4. Not to remove the matrix before setting of the restoration and be careful while removing it
5. To await disappearance of the lustre of the restoration before contouring
6. To round the edge of the proximal margin of the restoration and to check the occlusion after making sure that the restoration border is positioned correctly
7. To use hand instruments that are not sticking to the unmaturing restorative for the adaptation to the cavity walls
8. To thermo-cure the restoratives with LED light curing units before polishing
9. To use the coating

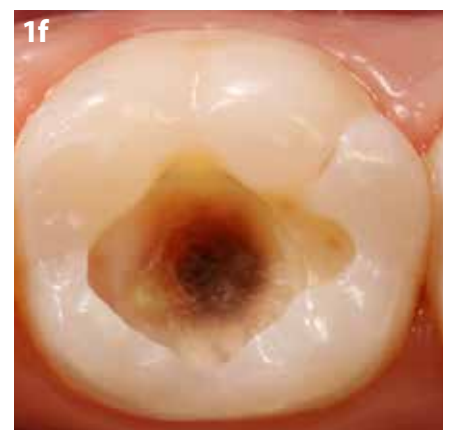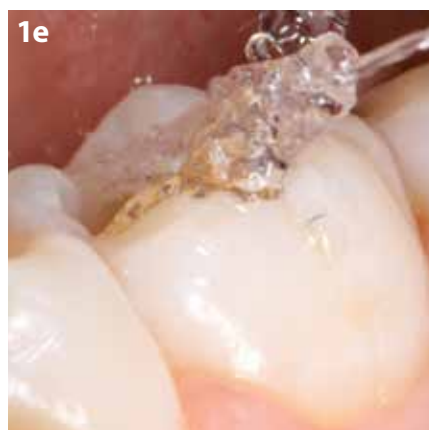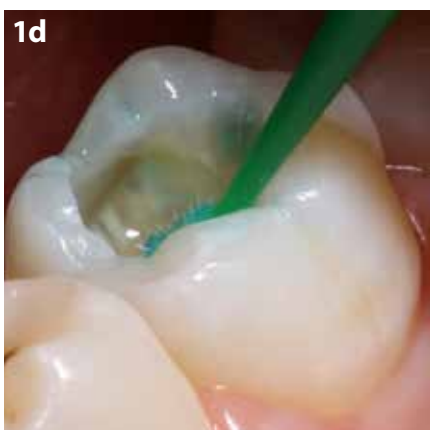
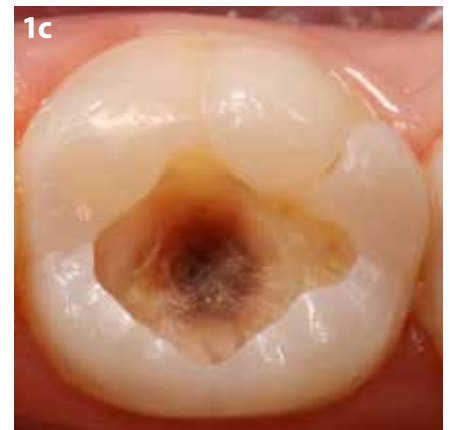
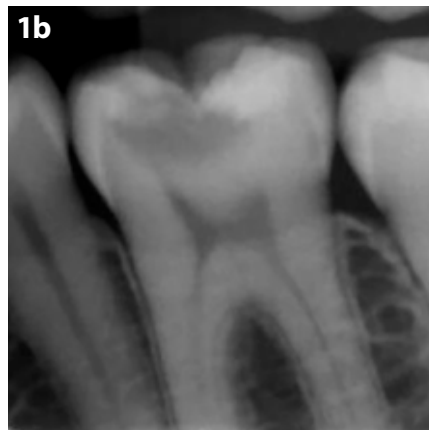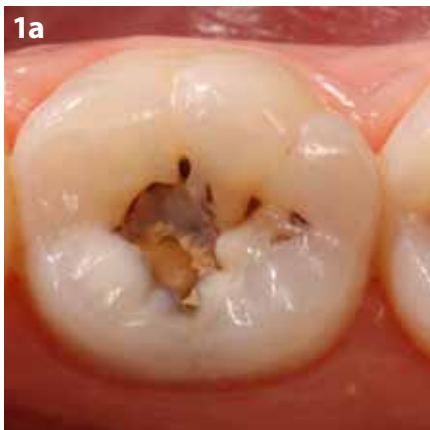## An aesthetic and biomimetic approach with a glass hybrid for direct restorations

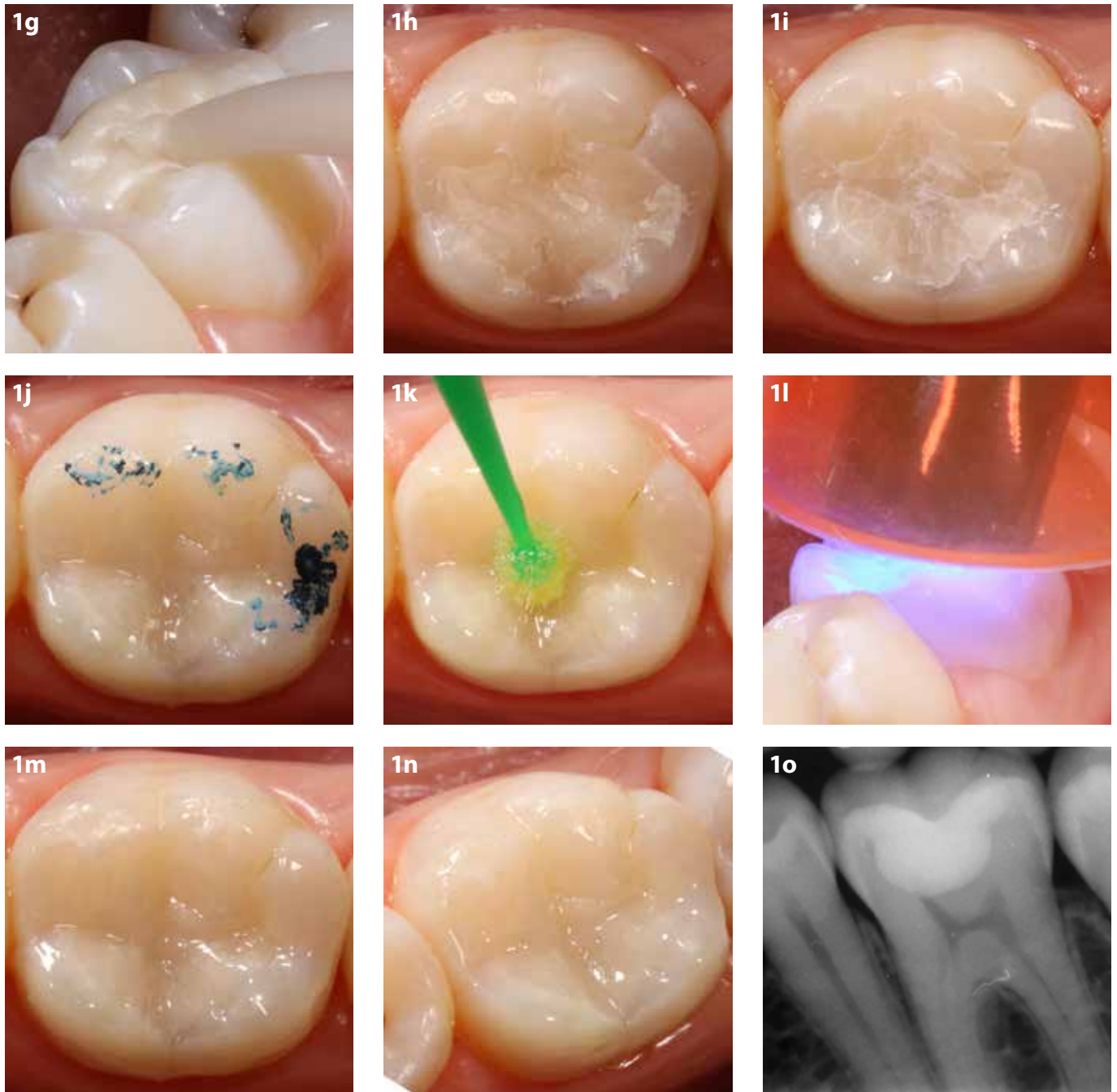
### Case 1

EQUIA Forte HT was used in a 34-year-old female patient for the emergency treatment of a vital lower first molar (tooth 36) with a deep, large carious lesion (Fig 1a). The vitality of the tooth was first determined by pulp testing and a radiograph was taken to check the depth of the lesion (Fig 1b). Local anaesthesia was applied and caries was removed using tungsten carbide burs (Busch "AU" Carbide Burr - TF1AU). Infected dentine was removed with an excavator (Fig 1c). The cavity walls were cleaned with 20% polyacrylic acid (Cavity conditioner, GC) during 10 s (Fig 1d), rinsed thoroughly with water (Fig 1e) and dried gently (Fig 1f).

EQUIA Forte HT capsules were prepared and mixed for 10 s, then restorative was directly applied into the cavity in a sufficient quantity using a bulk-fill technique with a special applicator (Fig 1g). EQUIA Forte HT was condensed against the cavity with a plastic hand instrument and was allowed to set undisturbed for approx. 2.5 min (Fig 1h). This restorative does not require a special surface coating during the setting reaction. The finishing process was performed with the use of rotary instruments in 2 steps: a) tapered trimming & finishing tungsten carbide burs were used for forming the fissures and occlusal anatomy of the

restoration; b) flame-shaped rubber points (blue and gray) were used for polishing (Fig 1i). All burs and polishers were used under water irrigation to avoid over-drying the restorative. The occlusal contact points were checked (Fig 1j). A final layer of the coating agent (EQUIA Forte HT Coat) was applied on the surface of the restoration without air-blowing (Fig 1k), then it was light-cured for 20 s with a D-Light DUO LED curing device at  $1400 \text{ mW/cm}^2$  (Fig 1l). The final clinical and radiographic views of the restoration are shown in Figures 1m-o, demonstrating excellent contour and aesthetics.





**Figure 1.** Treatment of a deep occlusal carious lesion with EQUIA Forte HT. **a.** Clinical view of a deep occlusal carious lesion with cavitation in a mandibular left first molar is shown. **b.** Bite-wing radiograph of deep occlusal carious lesion in a mandibular left first molar. **c.** Clinical view of the cavity after removing the caries lesion. **d-f.** Application of cavity conditioner. **g.** Application of the EQUIA Forte HT to the cavity. **h.** Clinical view of the restoration before polishing. **i.** Clinical view of the restoration after polishing. **j.** Occlusion check with articulation paper. **k.** Application of EQUIA Forte HT Coat onto the restoration surface. **l.** Light-curing of EQUIA Forte HT Coat. **m-n.** Clinical view of the restoration. **o.** Radiograph of the restoration.



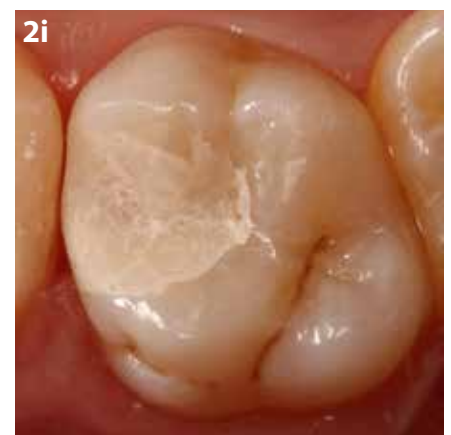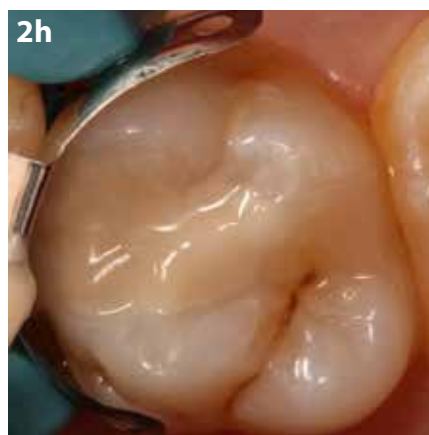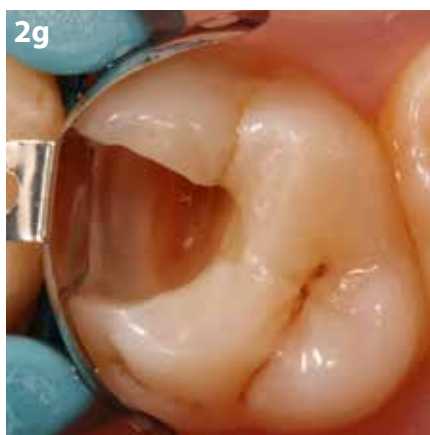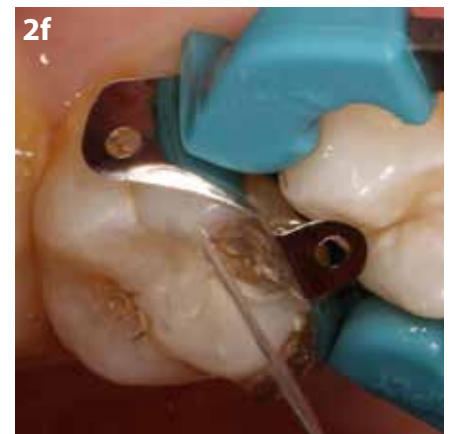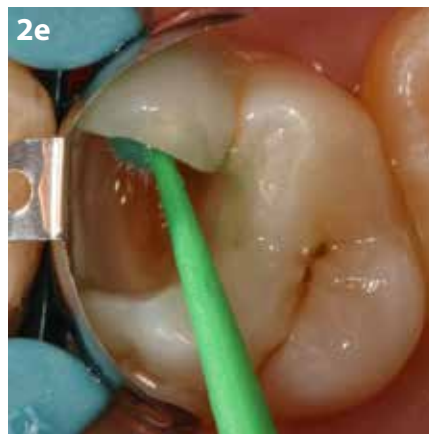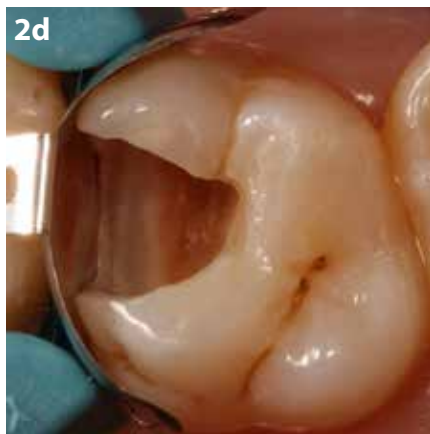
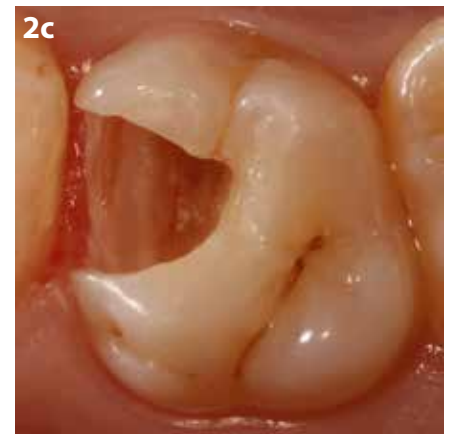
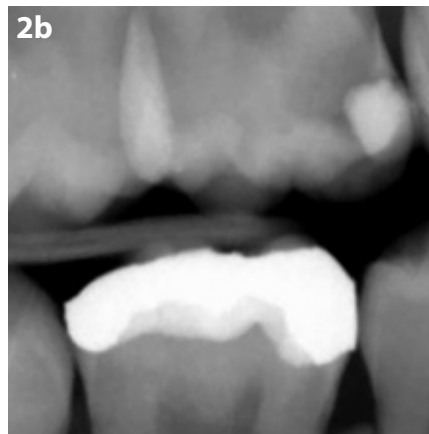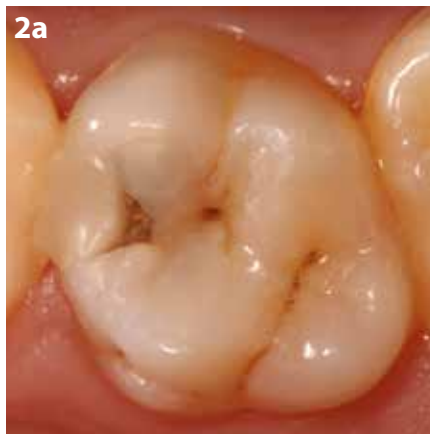## An aesthetic and biomimetic approach with a glass hybrid for direct restorations

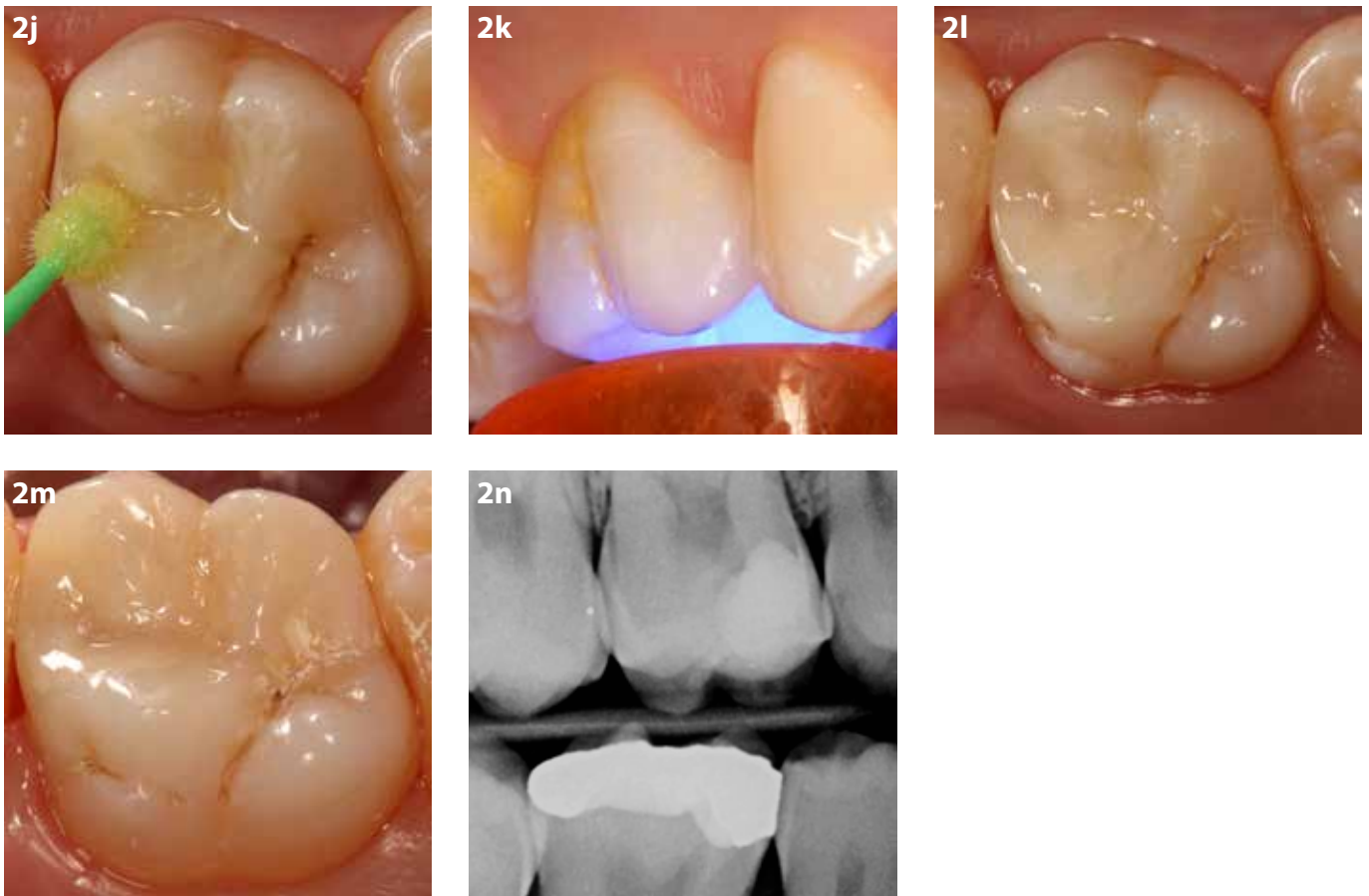
### Case 2

Case 2 is shown in Figure 2 and 3. In addition to the procedures performed in the first case, a sectional matrix system was used for the restoration of the Class II cavities in this case and for contouring the marginal ridges of the restorations, coarse/medium (40 µm) polishing discs were used. A 19-year-

old male patient presented with a history of a high caries rate and a high incidence of recurrent caries. In Figure 2, a failing composite restoration in a maxillary right first molar in need of replacement is shown. The old MO composite restoration was removed and secondary caries was excavated.

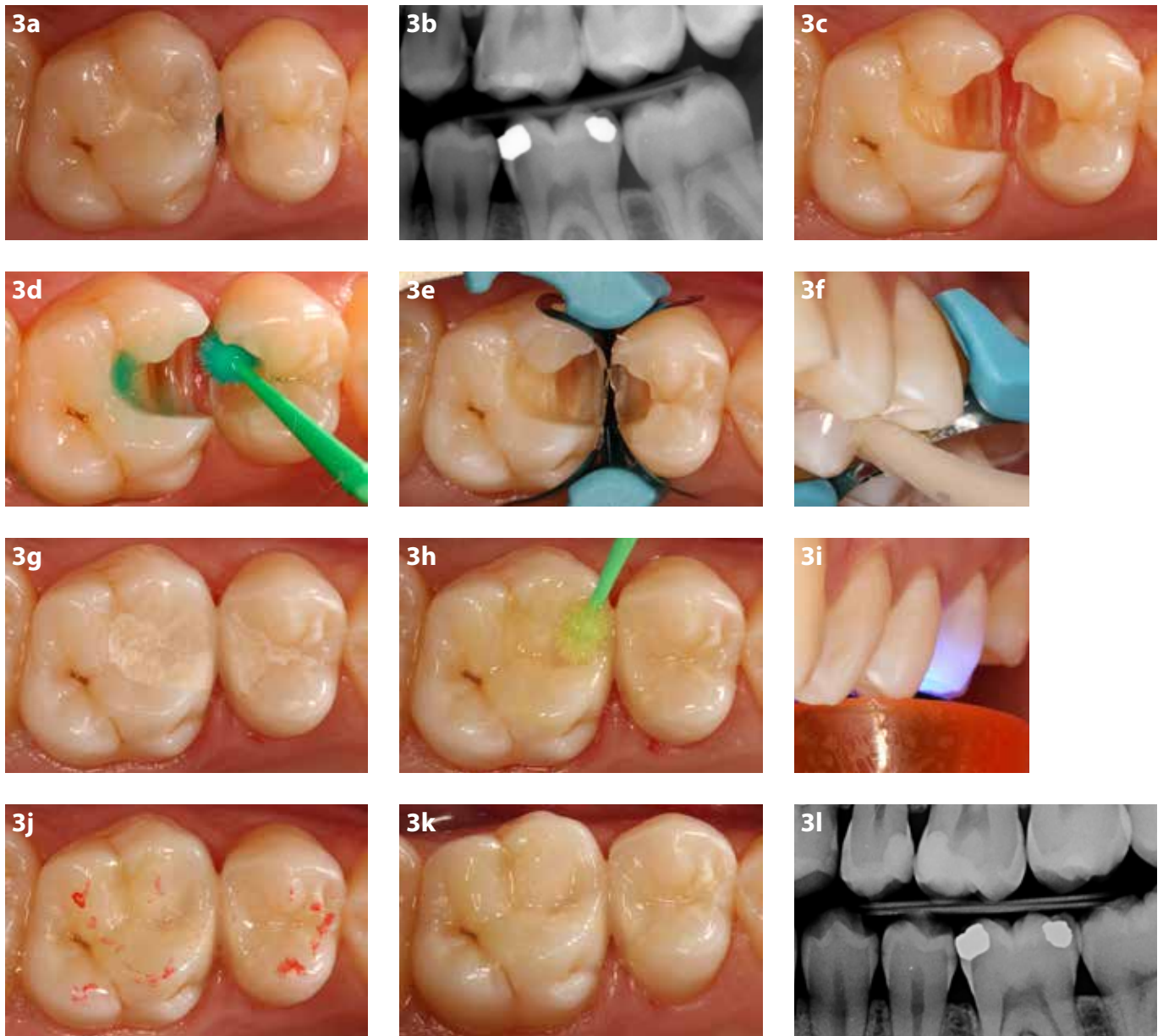
To decrease the likelihood of further recurrent caries, EQUIA Forte HT was preferred instead of composite for the restoration replacement. In Figure 3, the treatment steps of primary proximal carious lesions in the maxillary left second premolar and first molar are shown.





**Figure 2.** Treatment of a deep proximal secondary carious lesion with EQUIA Forte HT. **a.** Clinical view of a deep proximal secondary carious lesion with cavitation in an upper right first molar is shown. **b.** Bitewing radiographic view of deep occlusal carious lesion in an upper right first molar. **c.** Clinical view of the cavity after removing the old composite restoration and caries lesion. **d.** Placement of sectional matrix to perform proximal contact. **e-g.** Application of cavity conditioner. **h.** Application of the EQUIA Forte HT to the cavity. **i.** Clinical view of the restoration after removing the sectional matrix metal band and polishing. **j.** Application of EQUIA Forte HT Coat to the restoration surface. **k.** Light curing of EQUIA Forte HT Coat. **l-m.** Clinical views of the restoration. **n.** Radiograph of the restoration.

An aesthetic and biomimetic approach with a glass hybrid for direct restorations



**Figure 3.** Treatment of contacted proximal carious lesions with EQUIA Forte HT. **a.** Clinical view of two adjacent proximal carious lesions with cavitation in an upper left first molar and second premolar is shown. **b.** Bite-wing radiographic view of proximal carious lesions in an upper left first molar and second premolar. **c.** Clinical view of the cavities after removing caries lesions. **d.** Application of Cavity Conditioner. **e.** Placement of sectional matrix system to create the proximal contacts. **f.** Application of the EQUIA Forte HT to the cavities. **g.** Clinical view of the restoration after removing the sectional matrix metal band and polishing. **h.** Application of EQUIA Forte HT Coat on the restoration surfaces. **i.** Light-curing of EQUIA Forte HT Coat. **j.** Occlusion check with articulation paper. **k.** Clinical views of the restorations. **l.** Radiographic views of the restorations.

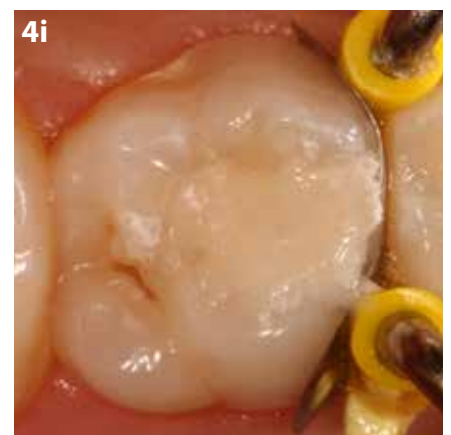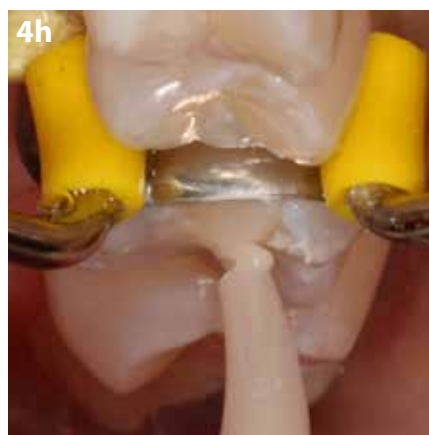
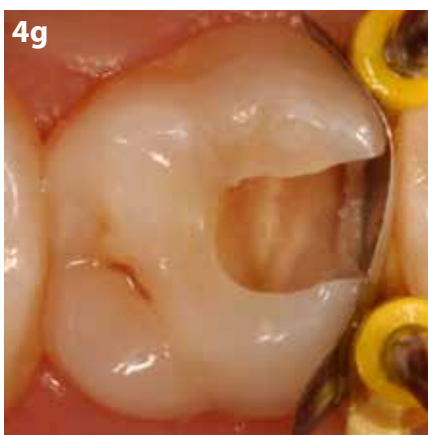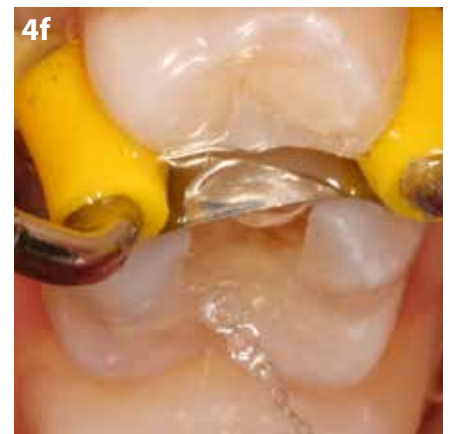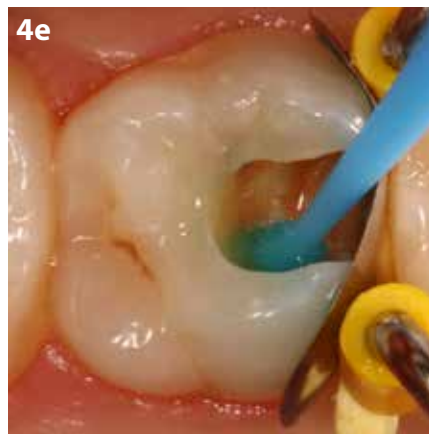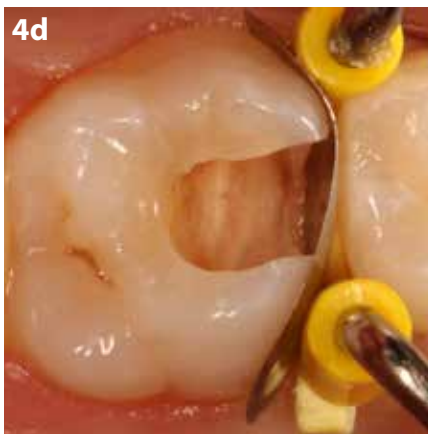
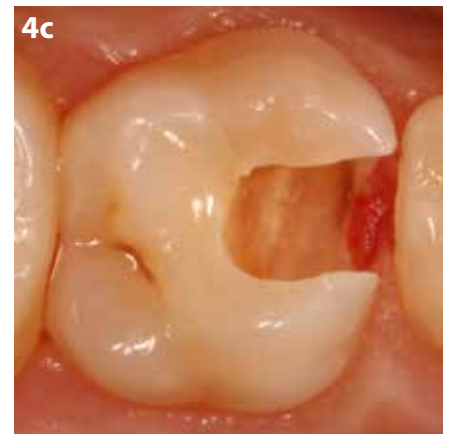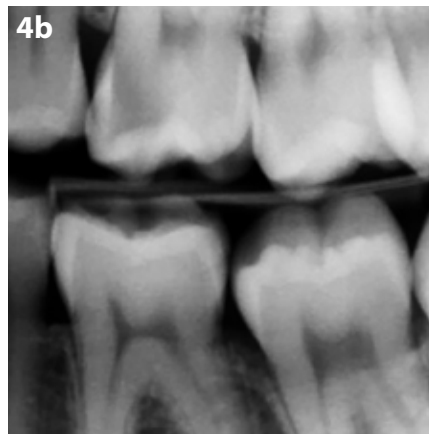


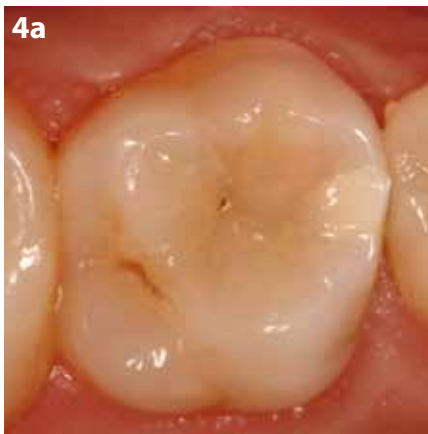### Case 3

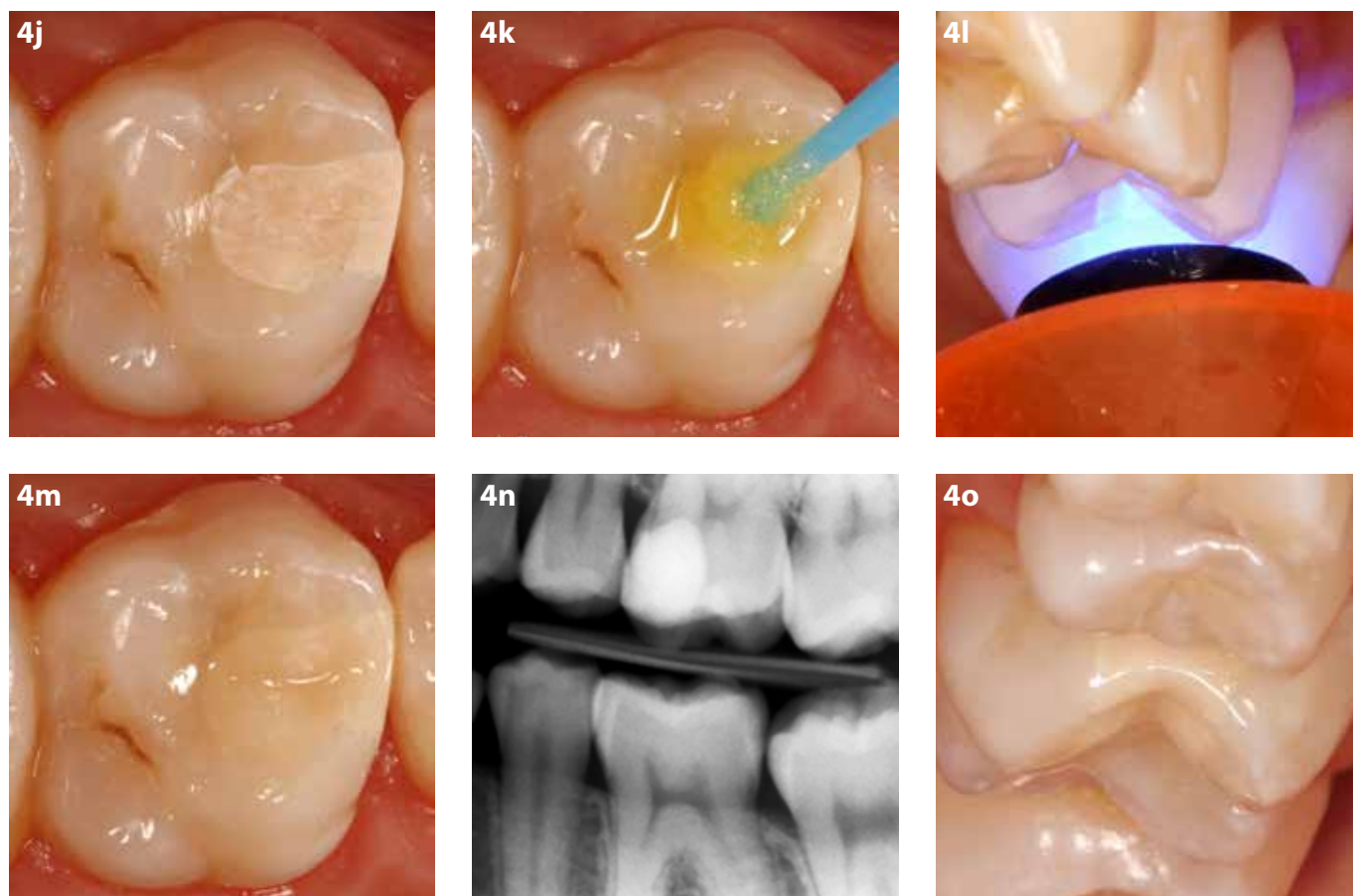
Case 3 is shown in Figure 4. A 22-year-old female patient with a deep proximal caries lesion in the left maxillary first molar was presented. To eliminate the post-operative

sensitivity and aesthetic disquiet it was preferred to restore the cavity with EQUIA Forte HT instead of composite. In Figure 4, the treatment steps of a deep proximal caries lesion

in left maxillary first molar is demonstrated.



## An aesthetic and biomimetic approach with a glass hybrid for direct restorations



**Figure 4.** Treatment of a deep proximal carious lesion with EQUIA Forte HT. **a.** Clinical view of a deep proximal carious lesion in an upper left first molar is shown. **b.** Bitewing radiograph of deep proximal carious lesion in an upper left first molar. **c.** Clinical view of the cavity after removing caries lesion. **d.** Placement of sectional matrix to create the proximal contact. **e-g.** Application of cavity conditioner. **h-i.** Application of the EQUIA Forte HT to the cavity. **j.** Clinical view of the restoration after polishing. **k.** Application of EQUIA Forte HT Coat to the restoration surface. **l.** Light-curing of EQUIA Forte. **m.** Clinical view of the restoration. **n.** Radiograph of the restoration. **o.** Clinical view of the margin of the restoration from different side.

## References

1. Wilson AD, Kent BE. A new translucent cement for dentistry. The glass ionomer cement. *Br Dent J.* 1972;132:133-135.
2. Davidson CL. Advances in glass-ionomer cements. *J Appl Oral Sci.* 2006;14 Suppl:3-9.
3. Peumans M, Kanumilli P, De Munck J, Van Landuyt K, Lambrechts P, Van Meerbeek B. Clinical effectiveness of contemporary adhesives: a systematic review of current clinical trials. *Dent Mater.* 2005;21:864-881.
4. Combe EC, Burke FTJ, Douglas WH. *Clinical Dental Materials.* Kluwer Academic Publishers; 1999.
5. Frankenberger R, Garcia-Godoy F, Kramer N. Clinical Performance of Viscous Glass Ionomer Cement in Posterior Cavities over Two Years. *Int J Dent.* 2009;781462. doi: 10.1155/2009/781462.
6. Gurgan S, Kütük ZB, Ergin E, Oztas SS, Cakir FY. Clinical performance of a glass ionomer restorative system: a 6-year evaluation. *Clin Oral Investig.* 2017;21:2335-2343.
7. Gurgan S, Kütük ZB, Ergin E, Oztas SS, Cakir FY. Four-year randomized clinical trial to evaluate the clinical performance of a glass ionomer restorative system. *Oper Dent.* 2015;40:134-143.
8. Diem VT, Tyas MJ, Ngo HC, Phuong LH, Khanh ND. The effect of a nano-filled resin coating on the 3-year clinical performance of a conventional high-viscosity glass-ionomer cement. *Clin Oral Investig.* 2014;18:753-759.
9. Basso M, Brambilla E, Benites MG, Giovannardi M, Ionescu AC. Glassionomer cement for permanent dental restorations: a 48-months, multi-centre, prospective clinical trial. *Stoma Edu J.* 2015;2:25-35.
10. Turkun LS, Kanik O. A Prospective Six-Year Clinical Study Evaluating Reinforced Glass Ionomer Cements with Resin Coating on Posterior Teeth: Quo Vadis? *Oper Dent.* 2016;41:587-598.
11. Kütük ZB, Ergin E, Yalcin FY, Gurgan S. 8-Year Clinical Evaluation of a Glass Ionomer Restorative System. *J Dent Res.* 2017;96B(0287).
12. Kütük ZB, Ozturk C, Soleimani R, Yalcin FY, Gurgan S. Clinical Performance of a Glass-Hybrid Restorative in Extended-Size Class-II Cavities. *Int*