



Pieter-Jan Swerts graduated in General Dentistry at the Catholic University of Leuven (Belgium) in 2017. After this, he continued with a 3-year Master program in Restorative Dentistry at the same university. During this program he developed a special interest for adhesive and digital dentistry. He is currently working in Icarus Dental, a multidisciplinary group practice in Antwerp (Icarus Dental), focusing on prosthetic and restorative dentistry.

Treatment of generalised tooth wear with the injection moulding technique

By Dent. Pieter-Jan Swerts, Belgium

Patients with severe generalised tooth wear may need complex restorative care, most often consisting of full rehabilitation at an increased vertical dimension of occlusion (VDO). It goes without saying that this type of treatment is usually challenging and time consuming. In general, minimum-intervention approaches should be considered first.

A 23-year-old patient consulted the dental clinic with concerns related to the condition of his teeth. The following case report describes a predictable workflow for a full-mouth rehabilitation with the injection moulding technique, as well as the rationale behind the method and practical advice for a feasible implementation.

Diagnosis

Examining the smile, short clinical crowns and a gummy smile were noted (Fig. 1a). Intraoral clinical examination revealed excessive tooth

wear at an extent that was obviously disproportional for the patient's age (Figs. 1b, 2). This finding, together with his complaints such as mild hypersensitivity, led to categorise the wear as pathological.^{1,2}

Cupping of the cusps resulted in exposure of dentinal tissue; this pattern is indicating that an erosive factor plays a role, a hypothesis that is further supported by the present restorations standing proud. Clearly defined, glossy wear facets were also present, indicative of excessive attrition.

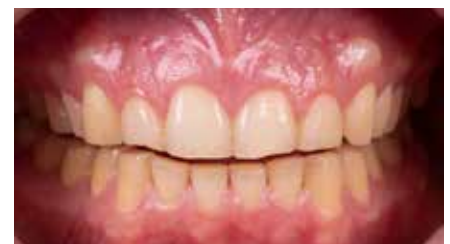
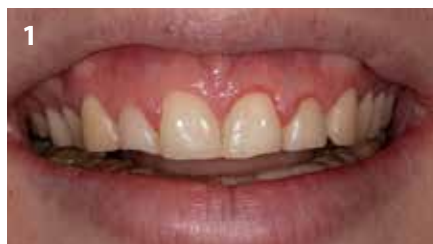
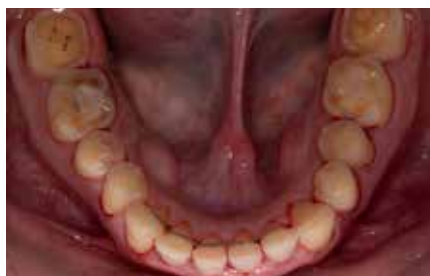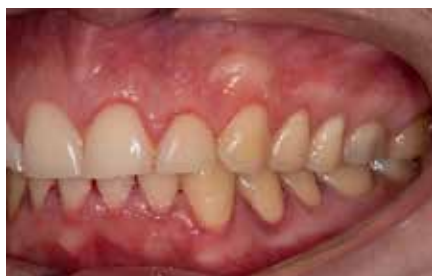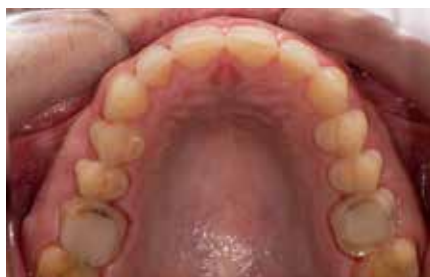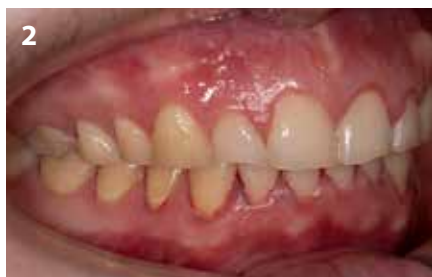Fig. 1: Initial situation, frontal view.



Intraoral scans and bite registration

Both jaws were scanned to register the initial situation. Due to the extreme wear, maximum intercuspation was not reliably reproducible. Because a change in the VDO was planned, the centric relation was used, to ensure a reliable assessment.

An anterior acrylic jig (Fig. 3) was used both as an anterior deprogrammer and as a guide to the extent of the occlusal preparation required. It was made a bit oversized at first and gradually reduced to the desired height to be able to evaluate its influence in a gradual manner.

Another method would be to use a leaf gauge (Fig. 4); in general, a 5 mm maximum increase in VDO can be justified to provide adequate space for the restorative material and to improve the aesthetics. Signs and symptoms after an increase below 5 mm tend to be self-limiting.^{7,8} By letting the patient move the mandible first forward and then back, the centric relation can be accurately

Fig. 2: Initial situation, intraoral view.

Aetiology

The aetiology of the wear was found to be multifactorial, with a chemical as well as mechanical component as stated above. This pattern, in which abrasive/attrition processes accelerate tooth surface loss after chemical softening by erosion, is quite often seen.^{2,3} Nightly bruxism, parafunction (nail biting, nut cracking) and erosion (carbonated soft drinks) were withheld from the anamnesis.

Prevention

It is important to keep in mind that restorations themselves do not prevent wear processes but merely alter them in terms of pattern and rate. Therefore, it is important to assess the likelihood of further wear and what form this may take, knowing that episodes of wear may well have different aetiologies.^{3,4}

To slow down further progression of the tooth wear, the patient was advised to reduce his intake of carbonated soft drinks, to stop nail biting and to avoid biting hard objects.

Treatment

After informed consent, we opted for a total rehabilitation of the wear with composite restorations using the injection moulding technique.

With the mechanical properties of current direct composite materials, evidence that supports their effectiveness for the management of all types of tooth wear on the medium to long term, is steadily growing.^{2,5,6} They offer an additive, minimally invasive alternative to achieve an aesthetically pleasing outcome for the treatment of tooth wear. Direct composite restorations are cost-effective and readily amenable to adjustment, repair, and refurbishment. Form and function are restored, and underlying tooth structures protected.

To resolve the gummy smile and improve the bite (Angle Class II), the option of orthodontic treatment with possible orthognathic surgery was discussed, but not accepted by the patient. To compensate for the gummy smile, a clinical crown lengthening was proposed as an alternative option.

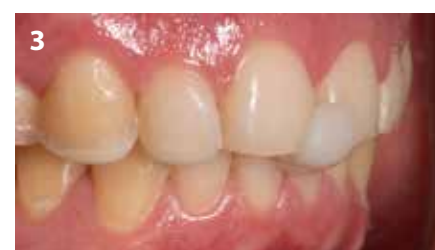

Fig. 3: Composite jig to determine the centric occlusion at the desired VDO.

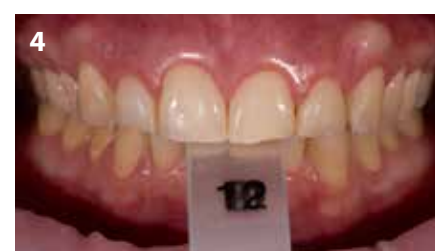

Fig. 4: A leaf gauge can also be used to determine the increase in VDO.

obtained. With the anterior jig, the mandible can be stabilized, which is necessary to digitally record the bite registration.⁹

Digital wax-up & mock-up

After having finished all scans (Fig. 5), a digital design was made and verified. Based on this 'digital wax-up', a mock-up was made in the mouth (Fig. 6). This is an important step in all complex treatments, which gives the opportunity to evaluate various aspects of the treatment, such as aesthetics, phonetics, and function, while adaptations are still possible. Moreover, the patient is informed about the treatment result he can expect. After patient approval of the proposed design, the 3D models and the transparent keys for in the injection could be fabricated.

3D models and transparent keys

For each jaw, two models were printed: one of the complete digital design and one where the teeth were alternately built up and the other teeth were left as in the original situation (Fig. 7).

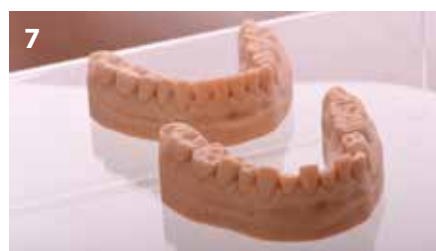

Fig. 7: 3D-printed models: one alternately restored and one fully restored model.

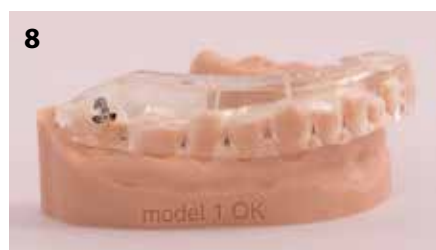

Fig. 8: Silicone keys from transparent silicone (EXACLEAR, GC): models were made for each quadrant and carefully trimmed, not to interfere with the rubber dam isolation.

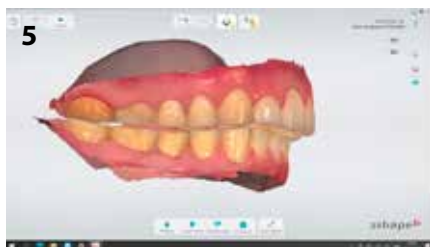

Fig. 5: Intraoral scans of the initial situation.

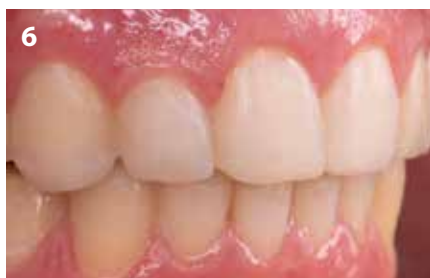
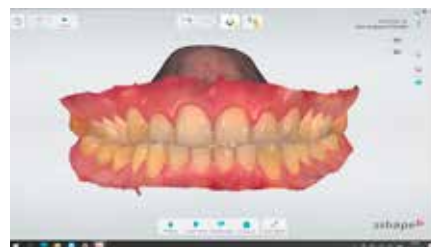
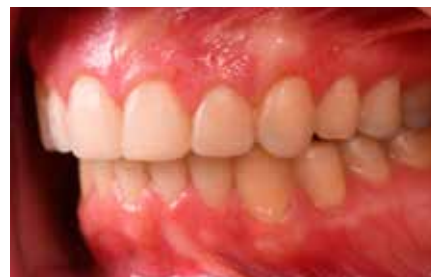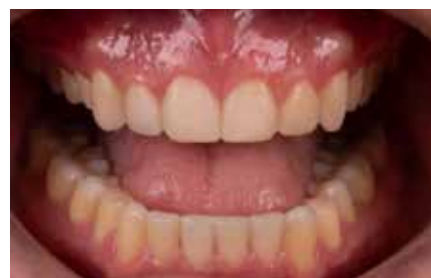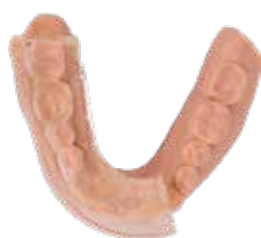Fig. 6: Intraoral mock-up of the computer-assisted restorative design.



Making use of these alternated models improves the stability of the transparent key because of the distinct and evenly distributed vertical stops. This results in an increased occlusal predictability and control over the proximal surfaces.

In total, 8 keys were made, with two keys for each quadrant (Fig. 8). Keys were made from clear vinyl polysiloxane (EXACLEAR, GC) in a non-perforated tray and were left to cure in a pressure vessel during 7 minutes at a pressure

of 2 bar. Due to the pressure, air bubble inclusion was prevented, facilitating the visual control through the key. It was ensured that the material had sufficient thickness (about 6-7 mm), vertically as well as horizontally, to ensure the rigidity of the key. Two holes per tooth were punched from the inside out with same needle as used for the injection: one for the injection and one as a vent to let composite excess escape.



Injection of flowable composite

Prior to the procedure, the closest matching shades were each tested on a tooth for the proper shade selection. Then, the teeth were isolated with rubber dam (Fig. 9). The keys were tried in and the margins were trimmed to avoid interference with the dam during passive seating. Next, the teeth were separated with metal matrix strips for the surface roughening with Al_2O_3 powder and selective enamel etching (Fig. 10). Where contact points were too heavy, these were slightly adjusted with 'New Metal Strips' (GC). After having thoroughly rinsed and dried, the alternating teeth were separated with PTFE tape. PTFE plugs were placed in the embrasures to avoid they would be filled with resin during the adhesive procedure and injection. Primer and bonding were applied and cured in accordance with the manufacturer's instructions (Fig. 11). Thereafter, the key was placed on the teeth, once again ensuring that it was stably seated prior to the injection of G-ænial Universal Injectable (Shade A2). After injection, each tooth was cured for at least 40 seconds (Fig. 12), hovering over all surfaces. When all teeth were built up, the key was taken off and each tooth was cured for at least 20 seconds again. Composite overhangs were removed with a scalpel (blade nr. 12; Fig. 13). When finished (Fig. 14), the workflow was repeated with the second key (Fig. 15). All quadrants were built up this way, each time following the same procedure (Fig. 16).

Finishing and polishing

Prior to the polishing, the sprue and surface irregularities due to composite overflow were removed with abrasive disks, fine diamond burs, interdental strips, and stones (Fig. 17). The occlusion was carefully checked, and premature and deflective contact points were

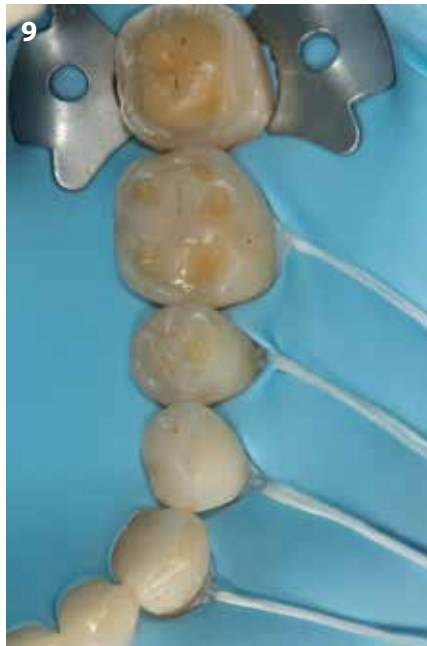

Fig. 9: The teeth were isolated with rubber dam prior to the adhesive procedure.

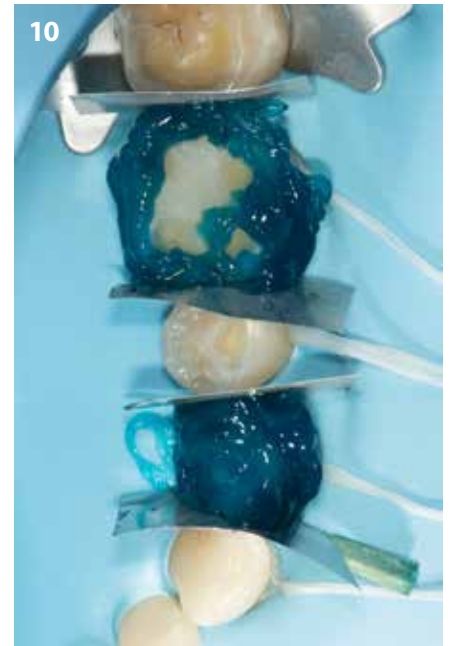

Fig. 10: Teeth were separated with metal matrices prior to sandblasting and selective enamel etching.

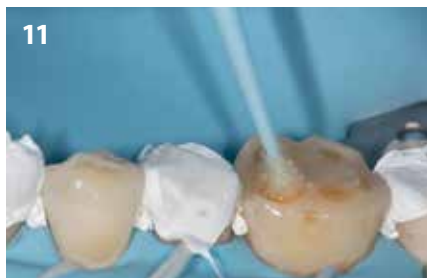

Fig. 11: Adhesive procedure with a two-step self-etch bonding system after careful placement of PTFE tape on the neighbouring teeth and in the interdental spaces.



Fig. 12: Each tooth was cured for at least 40 seconds.

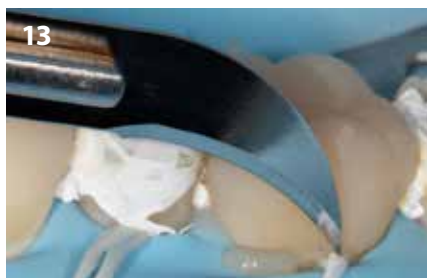


Fig. 13: Removal of overhang with a scalpel

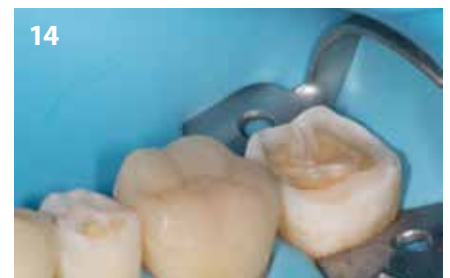

Fig. 14: After injection of the first silicone key (G-ænial A'CHORD, Shade A2)



removed. Because of the precise copying of the restoration design, only minor adjustments were needed.

An additional benefit of the composite injection technique is the absence of an oxygen-inhibited layer. This improves the polymerization of the surface layer¹⁰, which facilitates the polishing process. On the other hand, depending on the resolution and the print process, layer lines are visible on the 3D-printed model.¹¹⁻¹³ These layer lines are copied in the composite due to the high accuracy of the silicone key. They are, however, quickly removed with rubber polishing wheels (Fig. 18). Finally, the restorations were polished to high gloss with a brush and Diapolisher Paste.

The final result was a symmetrical dentition with balanced occlusal contacts (Fig. 19). While this outcome would be extremely difficult to obtain with a free-hand technique and requires a lot of skill and experience, an injection moulding technique can be mastered relatively fast. The patient was very happy with his restored dentition. A hard occlusal splint with canine guidance (Fig. 20) was provided to protect the restored teeth from nightly bruxism.¹⁴

Conclusion

Not all patients with signs of tooth wear require restorative treatment. Even though many of them may be effectively managed with a targeted preventive approach and sufficient monitoring, restorative intervention may be inevitable in the presence of severe pathological tooth wear, as in the described case.

To ensure a useful approach, the treatment should be attainable, stepwise, adjustable, repairable, cost-effective and remaining tooth structure needs to be preserved.¹⁵ The

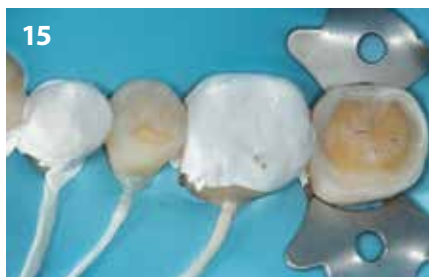

Fig. 15: All steps were repeated with the second silicone key...

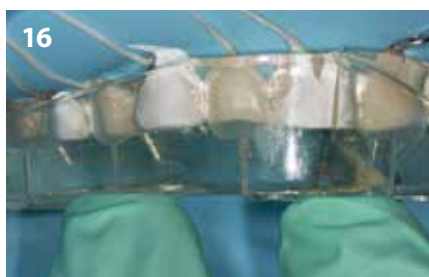


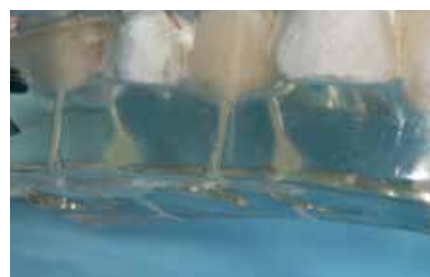
Fig. 16: ... and all done over to build up the other quadrants.

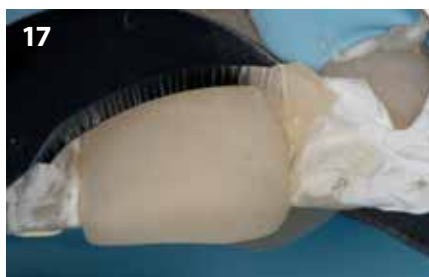
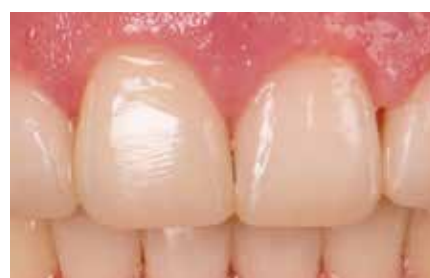
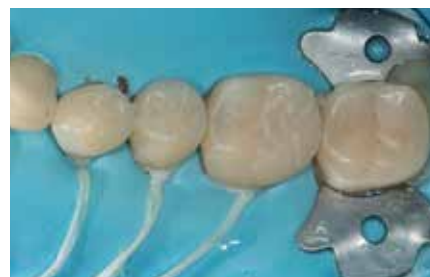Fig. 17: Finishing with scalpel (blade nr. 12) and interdental strips (New Metal Strips, GC).



Fig. 18: The layer line pattern copied from the 3D printed model can be removed with simple polishing procedures.



composite injection technique fulfils all these requirements. The treatment is minimally invasive, with minimal preparation requirements and an easily repairable material.^{16,17} Moreover, adjustments can relatively easy be made in a later phase if necessary, after the patient has had time to adjust

to the new situation but cannot get fully accustomed.

According to recent literature, resin composites are suitable for interim treatment as well as definitive treatment. Eliminating all the etiological factors, however, may be unrealistic when

patients suffer from persistent bruxism or are not willing or able to change potentially harmful habits. In such cases, it is possible that damage will reoccur.² Then, it can be considered to restore the dentition with indirect materials, such as glass ceramics. These are, however, more invasive in nature and adjustments are very difficult to make in a post-treatment phase. Therefore, it's preferred to reserve this type of treatment for a later phase.

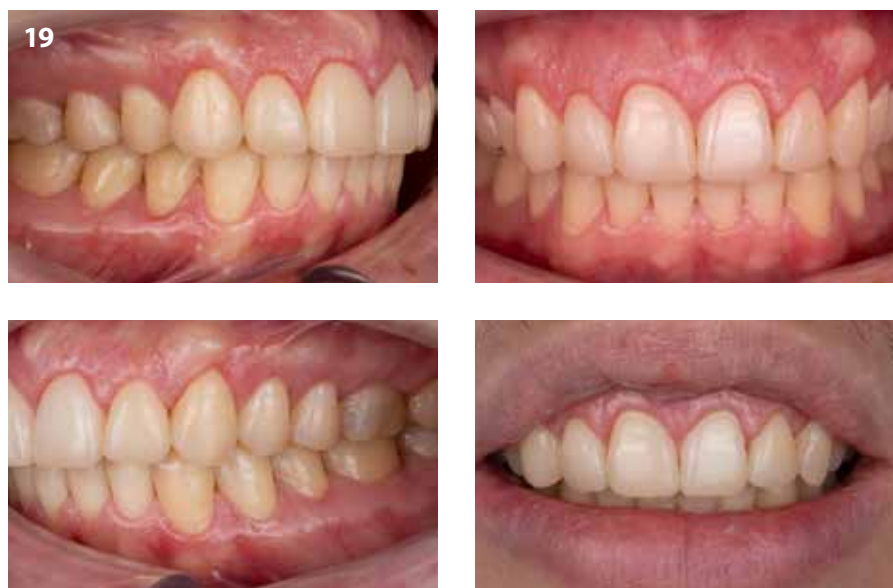

Fig. 19: Treatment result. With careful treatment planning and a reliable procedure, excellent morphology and balanced occlusal contacts were obtained with direct composite.

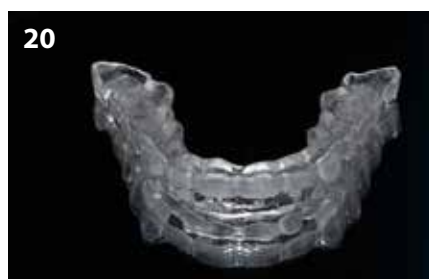

Fig. 20: Occlusal night guard.

References:

1. P. Wetselaar, M.J.M. Wetselaar-Glas, L.D. Katzer, M.O. Ahlers. Diagnosing tooth wear, a new taxonomy based on the revised version of the Tooth Wear Evaluation System (TWES 2.0). *J Oral Rehabil*, 47 (2020), pp. 703-712.
2. Loomans B, Opdam N, Attin T, Bartlett D, Edelhoff D, Frankenberger R, Benic G, Ramseyer S, Wetselaar P, Sterenborg B, Hickel R, Pallesen U, Mehta S, Banerji S, Lussi A, Wilson N. Severe Tooth Wear: European Consensus Statement on Management Guidelines. *J Adhes Dent*, 2017;19(2):111-119.
3. Loomans BAC, Kreulen CM, Huijs-Visser HECE, Sterenborg BAMM, Bronkhorst EM, Huysmans MCDNJM, Opdam NJM. Clinical performance of full rehabilitations with direct composite in severe tooth wear patients: 3.5 Years results. *J Dent*, 2018;70:97-103.
4. Mehta SB, Lima VP, Bronkhorst EM, Crins L, Bronkhorst H, Opdam NJM, Huysmans MDNJM, Loomans BAC. Clinical performance of direct composite resin restorations in a full mouth rehabilitation for patients with severe tooth wear: 5.5-year results. *J Dent*. 2021 Sep;112:103743.
5. Mjör IA, Gordan VV. Failure, repair, refurbishing and longevity of restorations. *Oper Dent*. 2002;27(5):528-534.
6. Crins LAMJ, Opdam NJM, Kreulen CM, et al. Randomized controlled trial on the performance of direct and indirect composite restorations in patients with severe tooth wear. *Dent Mater*. 2021;37(11):1645-1654.
7. Abduo J, Lyons K. Clinical considerations for increasing occlusal vertical dimension of occlusion: a review. *Aust Dent J*, 2012;57:2-10.
8. Abduo J. Safety of increasing the VDO: a review. *Quintessence Int* 2012;43: 369-80.
9. Radu M, Radu D, Abboud M. Digital recording of a conventionally determined centric relation: A technique using an intraoral scanner. *J Prosthet Dent*, 2020;123(2):228-231.
10. Borges M, Silva G, Neves F, Soares C, Faria-E-Silva A, Carvalho R, Menezes M. Oxygen inhibition of surface composites and its correlation with degree of conversion and color stability. *Braz Dent J*. 2021;32(1):91-7.
11. Iftekar SF, Aabid A, Amir A, Baig M. Advancements and Limitations in 3D Printing Materials and Technologies: A Critical Review. *Polymers (Basel)*. 2023 May 30;15(11):2519.
12. Yousef H, Harris BT, Elathamna EN, Morton D, Lin WS. Effect of additive manufacturing process and storage condition on the dimensional accuracy and stability of 3D-printed dental casts. *J Prosthet Dent*. 2022 Nov;128(5):1041-1046. doi: 10.1016/j.prosdent.2021.02.028. Epub 2021 Mar 27.
13. Camardella L.T., Vilella O.V., van Hezel M.M., Breuning K.H. Accuracy of stereolithographically printed digital models compared to plaster models. *J. Orofac. Orthop*. 2017;78:394-402.
14. Korkut B, Tagtekin D, Murat N, Yanikoglu F. Clinical Quantitative Evaluation of Tooth Wear: A 4-year Longitudinal Study. *Oral Health Prev Dent*. 2020 Sep 4;18(1):719-729. doi: 10.3290/j.ohpd.a45075.
15. Muts EJ, van Pelt H, Edelhoff D, et al. Tooth wear: a systematic review of treatment options. *J Prosthet Dent*. 2014;112(4):752-759.
16. Terry DA, Powers JM. A predictable resin composite injection technique, Part I. *Dent Today*. 2014 Apr;33(4):96, 98-101.
17. Terry DA, Powers JM, Mehta D, Babu V. A predictable resin composite injection technique, part 2. *Dent Today*. 2014 Aug;33(8):12.